

Case Reports

Chorea Associated with High Titers of Antiphospholipid Antibodies in the Absence of Antiphospholipid Antibody Syndrome

Damoun Safarpour*, Sarah Buckingham & Bahman Jabbari

Department of Neurology, Yale University school of Medicine

Abstract

Background: Chorea associated with high titers of antiphospholipid antibodies in the absence of antiphospholipid antibody syndrome has been seldom reported.

Case report: An 89-year-old female developed persistent right side chorea associated with high titers of anticardiolipin antibody (antiphospholipid antibodies immunoglobulin (Ig)M, 45 MPL and 112 IgM aCL (MPL) after 3 months) but normal lupus anticoagulants. Her magnetic resonance imaging (MRI) showed no abnormality, but positron emission tomography (PET) demonstrated increased bilateral striatal metabolic activity, more on the left side. Her MRI showed no cause for chorea. The PET scan demonstrated a marked increase in the metabolic activity of the left basal ganglia.

Discussion: Her chorea remained unchanged over a 9-month follow-up period. The literature on chorea associated with high titers of antiphospholipid antibodies in the absence of antiphospholipid syndrome is reviewed.

Keywords: Chorea, antiphospholipid antibody, antiphospholipid syndrome, anticardiolipin antibody

Citation: Safarpour D, Buckingham S, Jabbari B. Chorea associated with high titers of antiphospholipid antibodies in the absence of antiphospholipid antibody syndrome. Tremor Other Hyperkinet Mov. 2015; 5. doi: 10.7916/D8DB80M9

*To whom correspondence should be addressed. E-mail: damoun.safarpour@yale.edu

Editor: Elan D. Louis, Yale University, USA

Received: December 19, 2014 **Accepted:** January 22, 2015 **Published:** February 13, 2015

Copyright: © 2015 Safarpour et al. This is an open-access article distributed under the terms of the Creative Commons Attribution–Noncommercial–No Derivatives License, which permits the user to copy, distribute, and transmit the work provided that the original author(s) and source are credited; that no commercial use is made of the work; and that the work is not altered or transformed.

Funding: None.

Financial Disclosures: None.

Conflict of Interest: The authors report no conflict of interest.

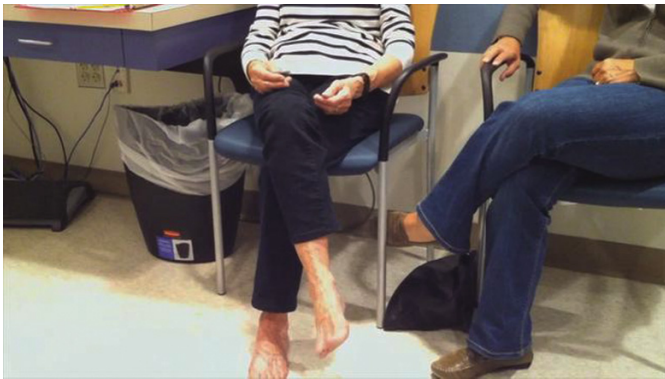Introduction

Chorea is a movement disorder characterized by involuntary, irregular, non-stereotyped movements of the limbs, trunk, neck, and face parts that can vary in frequency.¹ Chorea can be hereditary or non-hereditary. Among the hereditary choreas, Huntington’s disease is the most common; other less common hereditary choreas include chorea due to neuroacanthocytosis, Wilson’s disease, paroxysmal choreoathetosis, spinocerebellar ataxias, McLeod syndrome, Glucose transporter-1 deficiency syndrome (GLUT1) deficiency, dentatorubropallidolusian atrophy, Fahr’s disease, and Lesch–Nyhan syndrome. Non-hereditary choreas are most commonly caused by drugs and toxins,² followed by autoimmune disorders such as systemic lupus erythematosus (SLE), Sjögren’s syndrome, antiphospholipid antibody syndrome (APS), Sydenham’s chorea, chorea gravidarum, vascular and metabolic choreas,^{1,3,4} and paraneoplastic disorders.⁵

Low titers of antiphospholipid (aPL) antibodies have been reported in 2–9% of the normal population.^{6,7} Higher titers can be seen in people affected by certain viral or bacterial infections such as

mycoplasma, chlamydia, HIV, Lyme disease, and hepatitis C.^{8–10} Exposure to certain drugs such as hydralazine and procainamide is another cause of increased aPL titers.¹¹ APS is a hypercoagulable state characterized by the presence of at least one of the following clinical criteria of vascular thrombosis or pregnancy morbidity, in addition to the presence of one of the following antibodies: lupus anticoagulant (LAC or LA), anticardiolipin (aCL), or anti-β2 glycoprotein-I antibody (aβ2GPI).¹² Chorea is reported in 4% of the patients with lupus erythematosus^{13,14} and can be the first manifestation of lupus in children^{15–17} or even in late-onset SLE.¹⁸ The aCL antibody is the most frequently detected type of aPL antibodies in SLE, while LAC is the most frequent in SLE patients with chorea.^{16,19} In one study of 32 lupus patients with chorea, 27 patients (84%) had LAC, 19 (52%) had aCL, and 11 (34%) had aβ2GPI.¹⁹

It is the current belief that chorea associated with aPL antibodies occurs in the setting of fully developed APS. In recent years, however, there have been reports of chorea in patients with high titers of aPL antibodies in the absence of autoimmune disease or clinical APS.^{20,21}



Video 1. Choreiform movements involving both upper and lower limb, predominantly on the right side.

In this communication, we report another patient with chorea and high titers of aPL antibodies who does not fulfill the criteria for APS. The literature on aPL antibody titers, pathophysiology, neuroimaging, and treatment is also reviewed.

Case report

An 89-year-old female visited the Yale Movement Disorder clinic on August 2014 for evaluation of involuntary movements of the right side. She first noted subtle involuntary movements of her right hand and right foot in May 2014. The movements gradually increased in intensity but reached a plateau approximately 3 weeks prior to her clinic visit. A magnetic resonance imaging scan performed within a month after the onset of chorea showed mild bilateral microangiopathy in the white matter consistent with her age.

Her past medical history revealed resection of benign polyps in the colon 11 years earlier and a resection of an early stage skin melanoma 9 years previously without recurrence. She had two miscarriages during her youth. Her family history was negative for any neurological disorder or any medical disorder known to cause neurological problems. She did not drink, smoke, or use drugs.

On neurological examination she demonstrated excellent cognition for her age. The cranial nerves were intact. Speech was normal. There were continuous choreiform movements affecting the right upper and lower limbs, which were more prominent distally (Video 1). The face was spared. Subtle chorea was noted intermittently in the left foot. Her muscle strength was 5/5 and normal. There was no hypokinesia or rigidity. Deep tendon reflexes were 2+ and symmetrical. All modalities of sensation were normal. There were no cerebellar findings. Her gait was normal. An extensive blood works including assessment of hepatic and renal functions was normal. She had a normal antinuclear antibody and slightly increased sedimentation rate (28 mm/hour). The aPL antibody assessment revealed abnormal values: aCL IgM: 45 MPL (normal <12 MPL), phosphatidylserine antibody IgM of 54 MPL (normal <25 MPL), β 2 glycoprotein IgM was 34 SMU (standard IgM units) (normal <20 SMU). LACs were absent. Repeat magnetic resonance imaging (MRI) was unchanged from the first study. A deoxyglucose positron emission tomography (PET) scan showed

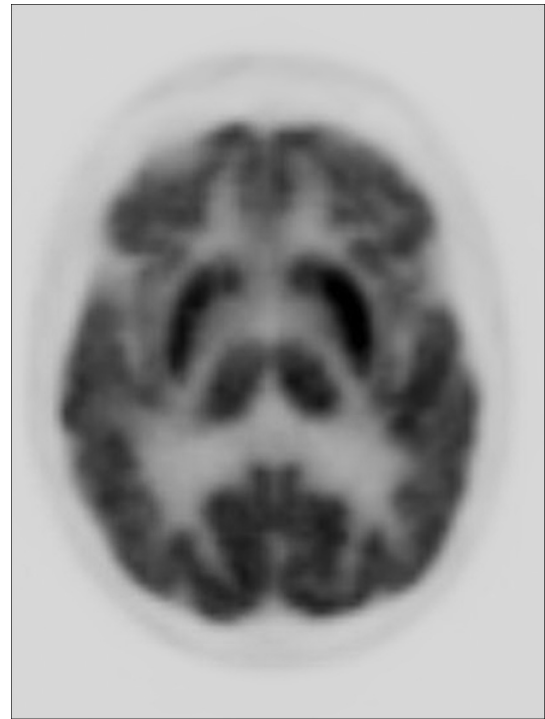


Figure 1. Deoxyglucose positron emission tomography shows bilaterally increased metabolic activity (putamen and caudate), more prominent on the left side.

markedly increased metabolic activity in the putamen and caudate nuclei bilaterally, more prominent on the left side, contralateral to the patient's chorea (Figure 1). She was treated with aspirin 81 mg/daily. An examination 3 months later showed no change in the pattern and intensity of chorea. The repeat aCL IgM value was 112 and β 2 glycoprotein IgM was 36.

Discussion

A review of the literature on the subject of chorea associated with a high titer of aPL antibodies without APS (pre-APS syndrome) revealed six previous publications: five single case reports and a small series of 10 patients (Table 1). Age of the reported patients varied from 5 to 21 years. Initial assessment of antibodies revealed an increased titer of aCL antibodies and absent LAC in all 15 patients. The majority of the patients, in addition to chorea, had other central nervous system findings such as seizures, dystonia, and dementia. All patients had normal magnetic resonance imaging. A repeat aPL antibody test demonstrating the persistently elevated titers was documented in only a few patients. PET was reported in one patient with unilateral chorea and showed increased metabolic activity over the contralateral basal ganglia. A variety of medications were tried in patients with moderate to severe chorea (Table 1). Follow-up evaluations beyond 6 months were reported in only three patients.

Our patient was considerably older than previously reported patients with pre-APS syndrome, but primary APS has been reported in elderly females with an age ranging from 65 to 79 years.^{14,22,23}

Table 1. Reported Cases of Chorea with Increased Antiphospholipid Antibody and Normal Lupus Anticoagulant Titers in Absence of Antiphospholipid Antibody Syndrome

Reference	N	Age (years)	Chorea Description	Other Symptoms	aPL Antibodies	MRI Findings	Treatment	Outcome
Kiechl-Kohlendorfer et al. ²⁹	1	5	Isolated left-side hemichorea	No	LAC – aCL IgM 28 aCL IgG 18	Normal	None	Chorea improved, aCL normalized
Usugi et al. ³⁰	1	6	Chorea started at age 4 months. At age 3 years, continuous bilateral arrhythmic rapid purposeless jerks of the arms and legs were noted	Myoclonic seizures developed at age 2 years	aCL (IgG) aCL +(99) IgM –, LAC – IgG level was decreased to 17 at age 6 years	Infarction in left MCA distribution at 3 months. Atrophy of basal ganglia, at age 3 years and additional atrophy of cerebellum at after 5 years	Methylprednisolone sodium succinate (10 mg/kg) for 3 days caused temporary improvement	Chorea and general condition gradually worsened
Biernacka-Zielinska et al. ³¹	1	16	Left upper limb chorea	?	Marked increase in aCL and aβ2GPI LAC first absent but present a year later	Not reported	Acetylsalicylic acid (75 mg/day) and risperidone	Chorea disappeared after 9 months
Shimomura et al. ³²	1	21	Onset at age 17, in the left hand, progressed to both hands, mouth/tongue	Unsteady gait and wild gyrations of the arms on walking	LAC – aCL +	MRI and CT NL	Not reported	Not reported
Sundén-Cullberg et al. ³³	1	20	Chorea started in right side of the body and face, later evolved into generalized chorea	Inability to eat and dress and dramatically impaired speech	LAC – aCL + (>100) ANA – ANCA –	MRI NL PET scan increased metabolism bilaterally more prominent in the lentiform nucleus and caudate and more on the left side. Repeat PET scan was normal after chorea subsided.	Pimozide and then after DC of pimozide, IV methylprednisolone	Deterioration after pimozide discontinued. Chorea ceased after IV methylprednisolone
Orzechowski et al. ³⁴	10	N/A	Mild six, moderate two, severe two Bilateral six Four patients: more than one episode	One generalized ataxia + seizures One epilepsy Two dysarthria + seizures One dementia Two dystonia	10 patients had LAC – and aCL + 71% of the non-APS patients had positive IgM aCL. IgM aCL in all patients with definite APS: all –	MRI was normal in all patients	Four patients received tetrabenazine-carbidopa/levodopa,risperidone-fluphenazine/ quetiapen Three received warfarin/heparin and four treated with aspirin. Three had immunosuppression	Partial response in seven and a complete response in three

Abbreviations: aβ2GPI, anti-β2 glycoprotein-I antibody; aCL, Anticardiolipin; ANA, Antinuclear Antibody; ANCA, Antineutrophilic Cytoplasmic Antibodies; aPL, Antiphospholipid; Ig, Immunoglobulin; IV, Intravenous; LAC, Lupus Anticoagulant; MRI, Magnetic Resonance Imaging; NL, normal; PET, Positron Emission Tomography. DC, Discontinuation.

Moderately raised titers of aPL have been reported in elderly patients with chorea and drug exposure, and immune and infectious disorders.²⁰ Our patient was in excellent health and did not have history of drug exposure or infection. She did not meet the criteria for APS due to absence of associated clinical conditions. Her miscarriages occurred almost 60 years ago. Her repeat aPL antibodies 3 months later showed further elevation of the titers. Her MRI showed no findings to explain the right-sided chorea. Although Huntington's disease is a consideration at any age, her excellent cognition, lack of family history and pattern of her chorea (predominantly unilateral over a follow up period of 9 months and sparing the face and tongue) made this diagnosis very unlikely.

At least two mechanisms have been proposed to account for the central nervous system damage caused by aPL antibodies. The first mechanism is that the antibodies have an affinity for the high phospholipid content of the endothelium of the brain vessels. They bind to the endothelium, which changes the permeability of the vessels. This results in breakdown of the blood-brain barrier, which contributes to hypercoagulation and thrombosis.^{24–26} The second mechanism is due to aPL antibody damage to the nigro-striatal pathway due to high binding affinity of aPL antibodies for phospholipid-rich neurons in dopaminergic pathway. The aPL-mediated depolarization causes dysfunction of neurons.²⁷ Breakeage of the blood-brain barrier by aPL antibodies also makes them more available to directly bind to neurons.

When aPL antibodies are detected but other criteria for definite diagnosis of APS are lacking, chorea and/or other findings such as livido reticularis, thrombocytopenia, valvular heart disease, and nephropathy (not currently included in the definition of APS) have been termed by some as a “Pre-APS” condition.^{20,21} Some authors suggest that pre-APS should be treated more aggressively in order to prevent thrombosis.²¹ The mechanism of chorea in pre-APS may be different from that seen in APS. While in APS (for example APS secondary to lupus) chorea is associated with thrombosis and elevated titers of the LAC antibody, pre-APS (our case and those listed in the table) is associated with an increase of aCL antibodies and a normal titer of LAC (Table 1). Regarding antibody subtypes, IgM was the most common subtype of aCL antibodies elevated in pre-APS patients (including our case). This suggests that high titers of the IgM subtype of aCL develop in pre-APS patients, and when the condition progresses to clinical APS, an increase in the IgG subtype occurs. Hence in the pre-APS condition, chorea is more likely the result of direct damage to the basal ganglia by aPL antibodies than occlusion of blood vessels, the latter being common in APS and often associated with an abnormal MRI. On the other hand, deoxyglucose PET scan shows an increased metabolic rate in the basal ganglia in pre-APS (our patient and that of Sundén-Cullberg et al.³³ in Table 1), and, hence, has higher diagnostic value than MRI in pre-APS patients with chorea. The relation between severity of chorea and aPL antibodies is not known. In fact, there have been patients with prominent chorea and low levels of aPL antibodies¹⁴ and even patients in whom aPL antibody levels remained high even 26 months after total remission from APS symptoms.²⁸

In APS, anticoagulants are typically used to reduce the risk of thrombosis, and several reports have indicated a reduction or even cessation of choreiform movements after such treatments.^{3,14} Since estrogen enhances dopaminergic sensitivity and can cause chorea in patients with APS, discontinuation of birth control pills high in estrogen is also recommended.¹⁴ In our patient, we chose to be conservative and treated her with aspirin 81 mg daily due to her advanced age. She developed no further symptoms but the chorea remained unchanged over a period of 9 months.

Although our patient's chorea and raised level of aPL antibodies could be coincidental, absence of other causes of chorea suggests that chorea resulted from direct action of aCL antibodies on the neural tissue (basal ganglia) similar to the previously reported patients with pre-APS (Table 1). We believe our patient and the current literature support the view that chorea can result from direct action of aCL antibodies on neural tissue of the basal ganglia in the absence of clinical APS. The challenge for the clinician is to decide how aggressively to treat patients with pre-APS syndrome in order to prevent thrombosis and other complications of APS. More data are needed on the natural history of patients with pre-APS and the evolution of pre-APS to APS in order to implement the best preventive strategy.

References

1. Walker RH. Differential diagnosis of chorea. *Curr Neurol Neurosci Rep* 2011; 11:385–395, doi: <http://dx.doi.org/10.1007/s11910-011-0202-2>.
2. Miyasaki JM. Chorea caused by toxins. *Handb Clin Neurol* 2011;100:335–346, doi: <http://dx.doi.org/10.1016/B978-0-444-52014-2.00026-4>.
3. Pandey S. Chorea. *J Assoc Physicians India* 2013;61:471–4, 483. Review
4. Bhidayasiri R, Truong DD. Chorea and related disorders. *Postgrad Med J* 2004; 80:527–534, doi: <http://dx.doi.org/10.1136/pgmj.2004.019356>.
5. Vighiani MC, Honnorat J, Antoine JC, et al. PNS EuroNetwork. Chorea and related movement disorders of paraneoplastic origin: The PNS EuroNetwork experience. *J Neurol* 2011;258:2058–2068, doi: <http://dx.doi.org/10.1007/s00415-011-6074-1>.
6. Shi W, Krilis SA, Chong BH, Gordon S, Chesterman CN. Prevalence of lupus anticoagulant and anticardiolipin antibodies in a healthy population. *Aust N Z J Med* 1990;20:231–236, doi: <http://dx.doi.org/10.1111/j.1445-5994.1990.tb01025.x>.
7. Vila P, Hernández MC, López-Fernández MF, Batlle J. Prevalence, follow-up and clinical significance of the anticardiolipin antibodies in normal subjects. *Thromb Haemost* 1994;72:209–213.
8. Vaarala O, Palosuo T, Kleemola M, Aho K. Anticardiolipin response in acute infections. *Clin Immunol Immunopathol* 1986;41:8–15, doi: [http://dx.doi.org/10.1016/0090-1229\(86\)90046-2](http://dx.doi.org/10.1016/0090-1229(86)90046-2).
9. Snowden N, Wilson PB, Longson M, Pumphery RS. Antiphospholipid antibodies and Mycoplasma pneumoniae infection. *Postgrad Med J*. 1990;66: 356–362, doi: <http://dx.doi.org/10.1136/pgmj.66.775.356>.
10. Avcin T, Toplak N. Antiphospholipid antibodies in response to infection. *Curr Rheumatol Rep* 2007;9:212–218, doi: <http://dx.doi.org/10.1007/s11926-007-0034-x>.

11. Bick RL, Baker WF. Antiphospholipid and thrombosis syndrome. *Semin Thromb Hemost* 1994;20:3–15, doi: <http://dx.doi.org/10.1055/s-2007-1001885>.
12. Miyakis S, Lockshin MD, Atsumi T, et al. International consensus statement on an update of the classification criteria for definite antiphospholipid syndrome (APS). *J Thromb Haemost* 2006;4:295–306, doi: <http://dx.doi.org/10.1111/j.1538-7836.2006.01753.x>.
13. Sanna G, Bertolaccini ML, Cuadrado MJ, et al. Neuropsychiatric manifestations in systemic lupus erythematosus: Prevalence and association with antiphospholipid antibodies. *J Rheumatol* 2003;30:985–992.
14. Cervera R, Asherson RA, Font J, et al. Chorea in the antiphospholipid syndrome. Clinical, radiologic, and immunologic characteristics of 50 patients from our clinics and the recent literature. *Medicine (Baltimore)*. 1997;76:203–212, doi: <http://dx.doi.org/10.1097/00005792-199705000-00006>.
15. Albishri JA. Chorea as a first manifestation in young patients with systemic lupus erythematosus who was initially diagnosed with rheumatic fever. *Clin Med Insights Case Rep* 2012;5:19–21, doi: <http://dx.doi.org/10.4137/CCRep.S9143>.
16. Iqbal S, Sher MR, Good RA, Cawkwell GD. Diversity in presenting manifestations of systemic lupus erythematosus in children. *J Pediatr* 1999;135:500–505, doi: [http://dx.doi.org/10.1016/S0022-3476\(99\)70174-5](http://dx.doi.org/10.1016/S0022-3476(99)70174-5).
17. Arisaka O, Obinata K, Sasaki H, Arisaka M, Kaneko K. Chorea as an initial manifestation of systemic lupus erythematosus. A case report of a 10-year-old girl. *Clin Pediatr (Phila)* 1984;23:298–300, doi: <http://dx.doi.org/10.1177/000992288402300514>.
18. Ariizumi Y, Ozawa T, Tokutake T, et al. Chorea as the first sign in a patient with elderly-onset systemic lupus erythematosus. *Case Rep Neurol Med* 2012;2012:317082.
19. Tarr T, Lakos G, Bhattoa HP, et al. Clinical thrombotic manifestations in SLE patients with and without antiphospholipid antibodies: A 5-year follow-up. *Clin Rev Allergy Immunol* 2007;32:131–137, doi: <http://dx.doi.org/10.1007/s12016-007-0009-8>.
20. Peluso S, Antenora A, De Rosa A, et al. Antiphospholipid-related chorea. *Front Neurol* 2012;3:150, doi: <http://dx.doi.org/10.3389/fneur.2012.00150>.
21. Asherson RA. New subsets of the antiphospholipid syndrome in 2006: “PRE-APS” (probable APS) and microangiopathic antiphospholipid syndromes (“MAPS”). *Autoimmun Rev* 2006;6:76–80, doi: <http://dx.doi.org/10.1016/j.autrev.2006.06.008>.
22. Carecchio M, Comi C, Varrasi C, et al. Complex movement disorders in primary antiphospholipid syndrome: A case report. *J Neurol Sci* 2009 Jun 15; 281:101–103, doi: <http://dx.doi.org/10.1016/j.jns.2009.03.011>.
23. Gelsa G, Tremolizzo L, Galbusera A, et al. Narrowing the window for ‘senile chorea’: A case with primary antiphospholipid syndrome. *J Neurol Sci* 2009 Sep 15;284:211–213, doi: <http://dx.doi.org/10.1016/j.jns.2009.05.009>.
24. Schmidt R, Auer-Grumbach P, Fazekas F, Offenbacher H, Kapeller P. Anticardiolipin antibodies in normal subjects. Neuropsychological correlates and MRI findings. *Stroke* 1995;26:749–754, doi: <http://dx.doi.org/10.1161/01.STR.26.5.749>.
25. Asherson RA, Hughes GRV. Antiphospholipid antibodies and chorea. *J Rheumatol* 1988;15:377–379.
26. Levine SR, Brey LR. Neurological aspects of antiphospholipid antibody syndrome. *Lupus* 1996;5:347–353.
27. Chapman J, Cohen-Armon M, Shoenfeld Y, Korczyn AD. Antiphospholipid antibodies permeabilize and depolarize brain synaptosomes. *Lupus* 1999;8:127–133, doi: <http://dx.doi.org/10.1191/096120399678847524>.
28. Wu SW, Graham B, Gelfand MJ, Gruppo RE, Dinopolous A, Gilbert DL. Clinical and positron emission tomography findings of chorea associated with primary antiphospholipid syndrome. *Movement disorders* 2007; 22:1813–1815, doi: <http://dx.doi.org/10.1002/mds.21657>.
29. Kiechl-Kohlendorfer U, Ellemunter H, Kiechl S. Chorea as the presenting clinical feature of primary antiphospholipid syndrome in childhood. *Neuropediatrics* 1999;30:96–98, doi: <http://dx.doi.org/10.1055/s-2007-973468>.
30. Usugi T, Nakano K, Nakayama T, Ishii K, Osawa M. Familial antiphospholipid antibody in a child with involuntary movement and deterioration. *Pediatr Int* 2007;49:238–241, doi: <http://dx.doi.org/10.1111/j.1442-200X.2007.02346.x>.
31. Biernacka-Zielinska M, Lipinska J, Szymanska-Kaluza J, Stanczyk J, Smolewska E. Recurrent arterial and venous thrombosis in a 16-year-old boy in the course of primary antiphospholipid syndrome despite treatment with low-molecular-weight heparin: A case report. *J Med Case Rep* 2013;7:221, doi: <http://dx.doi.org/10.1186/1752-1947-7-221>.
32. Shimomura T, Takahashi S, Takahashi S. Chorea associated with antiphospholipid antibodies. *Rinsho Shinkeigaku* 1992;32:989–93. [in Japanese]
33. Sundén-Cullberg J, Tedroff J, Aquilonius SM. Reversible chorea in primary antiphospholipid syndrome. *Mov Disord* 1998;13:147–149. Review, doi: <http://dx.doi.org/10.1002/mds.870130127>.
34. Orzechowski NM, Wolanskyj AP, Ahlskog JE, Kumar N, Moder KG. Antiphospholipid antibody-associated chorea. *J Rheumatol* 2008;35:2165–2170, doi: <http://dx.doi.org/10.3899/jrheum.080268>.