

Case Reports

The Management of Osteoarthritis in Movement Disorders: A Case Discussion

Giles H. Stafford¹, Robin S. Howard^{2*} & Jonathon Lavelle¹

¹Chelsea and Westminster Hospitals Foundation Trust, London, United Kingdom, ²National Hospital for Neurology and Neurosurgery, London, United Kingdom

Abstract

Background: A 37-year-old female with a hyperkinetic movement disorder due to chorea–acanthocytosis developed severe painful degenerative arthritis of her left knee as a consequence of repetitive involuntary flexion and extension dystonic and ballistic movements.

Case Report: Despite profound limitation in her mobility a total knee replacement was successfully undertaken.

Discussion: The case emphasizes that patients with progressive neurodegenerative disorders may derive relief or resolution of pain by joint replacement even if mobility does not improve following surgery. A multidisciplinary approach to care is essential.

Keywords: Neuroacanthocytosis, osteoarthritis, joint replacement

Citation: Stafford GH, Howard RS, Lavelle J. The management of osteoarthritis in movement disorders: a case discussion. Tremor Other Hyperkinet Mov 2013; 3: <http://tremorjournal.org/article/view/153>

*To whom correspondence should be addressed. E-mail: robin.howard@uclh.nhs.uk

Editor: Elan D. Louis, Columbia University, United States of America

Received: January 17, 2013 **Accepted:** March 4, 2013 **Published:** July 2, 2013

Copyright: © 2013 Stafford et al. This is an open-access article distributed under the terms of the Creative Commons Attribution–Noncommercial–No Derivatives License, which permits the user to copy, distribute, and transmit the work provided that the original author(s) and source are credited; that no commercial use is made of the work; and that the work is not altered or transformed.

Funding: None.

Conflict of interest: The authors report no conflicts of interest.

Financial disclosures: None.

Introduction

Orthopedic surgery is often undertaken to correct joint deformities or scoliosis in patients with neuromuscular disorders or cerebral palsy.¹ It also has an important role in the management of spasticity due to disorders of the central nervous system.^{2,3} However, it is unusual for joint replacement to be undertaken in patients with hyperkinetic movement disorders. This is surprising as repetitive movements of the limbs, such as tremor, chorea, dystonia, myoclonus, or ballismus, might be expected to lead to secondary degenerative change.

Case report

We present management of a 37-year-old female with a hyperkinetic movement disorder due to chorea–acanthocytosis who developed severe degenerative arthritis of her left knee as a consequence of repetitive involuntary flexion and extension dystonic and ballistic movements.

The patient presented with a progressive movement disorder at the age of 25 years, with a 2-year history of progressive stuttering and slurring of speech with chewing and swallowing difficulties due to repetitive perioral movements. A diagnosis of chorea–acanthocytosis was established by the finding of >20% acanthocytes on a fresh blood

film, and confirmed by absent chorein on Western blot. The abnormal movements continued and she developed progressive chorea and dystonic movements involving both arms and legs. In particular, she had worsening large-amplitude ballistic movements, and a worsening dystonia of her left and right foot became apparent on walking.

She developed increasing pain and limitation of the left knee. Her mobility was limited to using walking sticks around the home and a wheelchair outside. Her quality of life was rapidly deteriorating because of pain. By the time of presentation she was reliant on regular analgesia and had been forced to increasingly use her wheelchair, even around the house. Her functional level had dropped so that she was unable to climb stairs, and as a result her bed had been moved to the ground floor.

Examination revealed a slim lady with an exquisitely painful left knee. She demonstrated partially correctable varus alignment and a moderate effusion. Range of motion showed a fixed flexion deformity of 15°, flexing to a maximum of 90° with only partial quadriceps control.

Preoperative radiographs showed multiple large intra-articular loose bodies and severe generalized arthritic change with medial compartment bone loss (Figure 1).

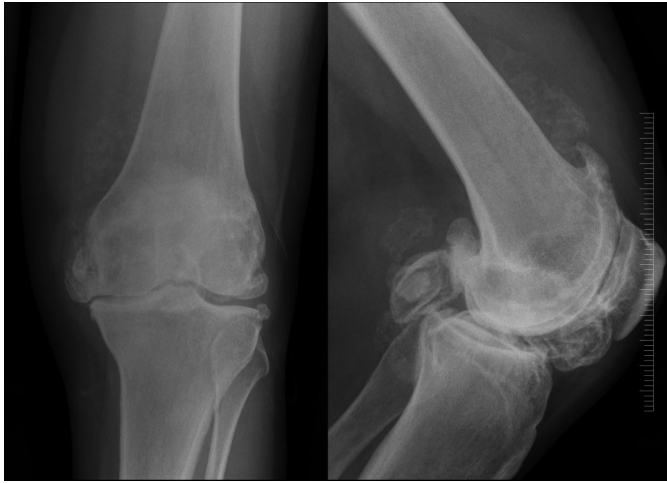


Figure 1. Preoperative Anteroposterior and Lateral Radiograph.

A Depuy PFC posterior stabilized total knee replacement (Depuy, Johnson & Johnson) was inserted via a midline incision and medial parapatellar approach in the standard manner with no unforeseen complications (Figure 2). There was no need for bone grafting or augmentation. The multiple and unusually large loose bodies were removed from the knee joint (Figure 3). In this case, a stemmed tibial tray was utilized, but there was no need for structural augmentation.

The patient recovered well and was discharged home on day 5 postoperatively. She was seen in the outpatients department at 4 weeks post procedure: the wound had healed well and range of motion was 5–10–100° (5° of fixed flexion, a further 5° extensor lag [a sign of quadriceps weakness]), and a full flexion range of 100°. Her symptoms of pain at this point were much better. She was subsequently seen again at 6 months, when her range of motion measured at 10–10–120°. The lack of full extension was due to her neurological condition leading to poor quadriceps control. She regained some of her lost mobility and was initially able to walk with a frame to assist her ambulation inside the house. Unfortunately, over the subsequent year, her mobility decreased and she became chair-bound because of a

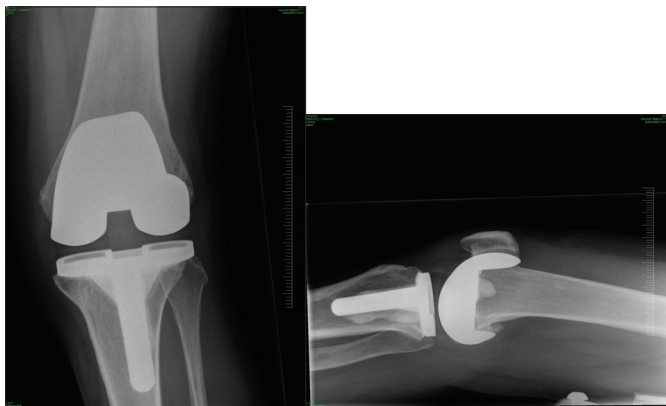


Figure 2. Postoperative Anteroposterior and Lateral Radiograph.

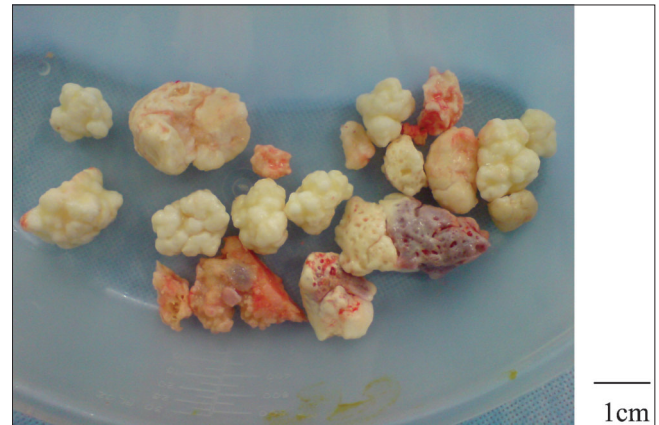


Figure 3. Intra-articular Loose Bodies Removed Perioperatively.
(Note standard kidney dish receptacle and therefore size.)

gradual deterioration in her neurological condition. The patient and her family however remain very pleased with the results of her surgery, and the knee continues to function in a stable and pain-free manner.

There have been no previous published cases of knee (or in fact any joint) osteoarthritis associated with chorea–acanthocytosis. We hypothesize that the progressive joint degeneration was caused by the patient’s left-sided repetitive involuntary dystonic flexion and extension movements causing repeated cartilage damage. This would certainly account for the large volume of large intra-articular loose bodies found perioperatively, and would also be suggested by the lack of any other joint involvement.

Discussion

Degenerative arthritis is commonly seen as a consequence of neurological disorders causing asymmetrical muscular weakness and secondary gait impairment. Cervical spondylosis or disc herniation leading to radiculopathy or myelopathy has been described as a result of severe motor tics in Tourette syndrome.⁴ It is particularly important in patients with focal wasting and weakness due to previous poliomyelitis or myopathic weakness. However, there are no previous reports of joint replacement being undertaken for arthritis associated with involuntary hyperkinetic movement disorders. This is surprising given the frequency of involuntary movements in the older population, including idiopathic Parkinson’s disease, essential tremor, and drug-induced dystonia. It is possible this is because movements are usually distal and relatively small amplitude. However, some patients do have larger amplitude proximal movements including ballismus and, as in the present case, dystonia.

The surgery can be challenging. Patients with neurological disorders may well require more constrained implants because of their lack of voluntary muscle control and possible ligamentous imbalance. With lack of proprioceptive feedback, bone loss can be an issue, and this is commonly seen in patients with insensate or “Charcot” joints. If this is the case, the surgeon needs to be aware of the possible need for bone augmentation with either metal augments or bone graft (auto or allograft). With regards to total knee replacement, the use of stemmed

implants must also be considered to impart the prosthesis with as much stability as possible to try and protect against early loosening in the presence of uncontrolled movements. With regards to total hip replacement, large-diameter articulations or constrained implants should be used to impart as much stability as possible.

In these cases, close discussion between orthopedic surgeons, neurologists, and anesthesiologists, as well as physio- and occupational therapy, is essential to try and maximize the patient's mobility. Minimizing any abnormal movements is also desirable, as these could have a detrimental effect on the survivorship of the implants if they are loaded in a repetitively abnormal manner.

It is important to recognize that patients with progressive neurodegenerative disorders may derive great and prolonged relief or complete resolution of distressing pain by joint replacement even if mobility remains severely impaired and does not improve following surgery. A multidisciplinary approach to care is essential.

Acknowledgment

Each of the authors was directly involved in the care of the patient and in the writing. Western blot analysis for chorein was performed by

Dr. Benedikt Bader with the financial support of the Advocacy for Neuroacanthocytosis Patients and of the ERA-net E-Rare consortium EMINA (European Multidisciplinary Initiative on Neuroacanthocytosis; BMBF 01GM1003) in the laboratories of Profs. Hans Kretzschmar (Neuropathology) and Adrian Danek (Neurology) at Ludwig-Maximilians-Universität Munich, Germany.

References

1. Barnes MP. Spasticity. In: Handbook of Neurological Rehabilitation. 2nd edition. Eds. RJ Greenwood, MP Barnes, TM McMillan, CD Ward. Psychology Press: Hove, 2003;157–170.
2. Queally JM, Abdulkarim A, Mulhall KJ. Total hip replacement in patients with neurological conditions. *J Bone Joint Surg Br* 2009;91:1267–1273, doi: <http://dx.doi.org/10.1302/0301-620X.91B10.22934>.
3. Houlden H, Charlton P, Singh D. Neurology and orthopaedics. *J Neurol Neurosurg Psychiatry* 2007;78:224–232, doi: <http://dx.doi.org/10.1136/jnnp.2006.092072>.
4. Krauss JK, Jankovic J. Severe motor tics causing cervical myelopathy in Tourette's syndrome. *Mov Disord* 1996;11:563–566, doi: <http://dx.doi.org/10.1002/mds.870110512>.