

## New Observations Letters

## An Unusual and Intriguing Presentation of Sydenham's Chorea

Sahil Mehta<sup>1\*</sup>, Manoj Kumar Goyal<sup>1</sup>, Camilla Kilbane<sup>2</sup>, Rajender Kumar<sup>3</sup> & Vivek Lal<sup>1</sup>

<sup>1</sup>Department of Neurology, Post Graduate Institute of Medical Education and Research, Chandigarh, IN, <sup>2</sup>Parkinson's and Movement Disorder Center, University Hospitals Case Medical Center, Cleveland, OH, USA, <sup>3</sup>Department of Nuclear Medicine and PET/CT, Post Graduate Institute of Medical Education and Research, Chandigarh, IN

**Keywords:** Chorea, antineuronal antibodies, intravenous immunoglobulin, dopamine receptor, Sydenham's chorea

**Citation:** Mehta S, Goyal MK, Kilbane C, Kumar R, Lal V. An unusual and intriguing presentation of Sydenham's chorea. Tremor Other Hyperkinet Mov. 2018; 8. doi: 10.7916/D8VM5W0N

\*To whom correspondence should be addressed. E-mail: mehtasahilpgi@gmail.com

**Editor:** Elan D. Louis, Yale University, USA

**Received:** July 28, 2018 **Accepted:** September 12, 2018 **Published:** October 9, 2018

**Copyright:** © 2018 Mehta et al. This is an open-access article distributed under the terms of the Creative Commons Attribution–Noncommercial–No Derivatives License, which permits the user to copy, distribute, and transmit the work provided that the original authors and source are credited; that no commercial use is made of the work; and that the work is not altered or transformed.

**Funding:** None.

**Financial Disclosures:** None.

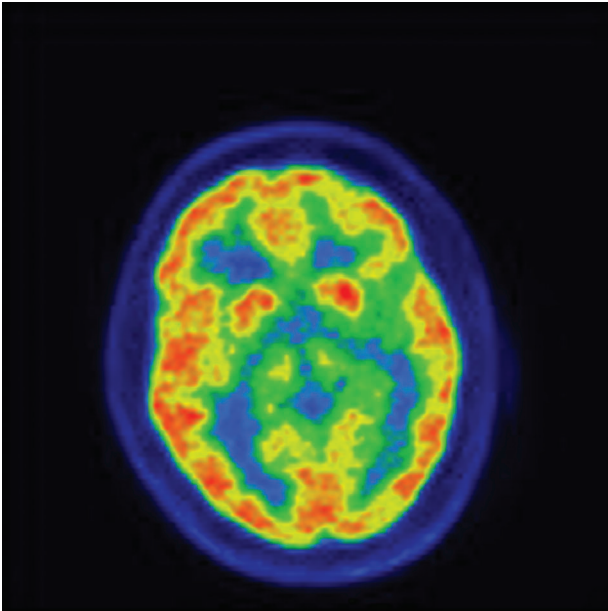
**Conflicts of Interest:** The authors report no conflict of interest.

**Ethics Statement:** All patients that appear on video have provided written informed consent; authorization for the videotaping and for publication of the videotape was provided.


A 26-year-old male born of a non-consanguineous marriage with normal birth and developmental history presented with abnormal movements for the last 15 years. He first noticed changes in his handwriting. The movements were jerky, non-stereotyped, and were associated with violent flinging movements. They were not preceded by any premonitory urge and were only partially suppressible. The movements gradually progressed to involve the face and neck, and, over the next 5 years, became generalized. His parents also complained of behavioral disturbances such as hyperactivity, aggressiveness, and obsessive-compulsive behavior. There was no history of cognitive decline, psychosis, seizures, or myoclonic jerks. Family history was non-contributory. There was no history of rheumatic fever, vasculitis, or exposure to toxins. The patient suffered frequent throat infections until the age of 5 years. He had been previously prescribed multiple medications, without significant improvement (tetrabenazine, haloperidol, valproate, clonazepam in various combinations).

General physical examination was normal. He was alert, oriented to time, place, and person. Pertinent examination findings included unclear speech and generalized hypotonia. Deep tendon reflexes were 2+ with bilateral flexor plantar response and no cerebellar signs. The movement disorder is depicted in the Video 1. Work-up for his generalized chorea was undertaken. His C-reactive protein and antistreptolysin (ASO) titers were normal. Vasculitic markers Rheumatoid factor (RF/ANA/dsDNA/C3/c-ANCA/p-ANCA/anti-Ro/La/anticardiolipin antibodies/APLA/LA), 24-hour urinary copper, ceruloplasmin levels,

PBF for acanthocytes, TSH, anti-TPO antibodies, anti-TTG, alpha-fetoprotein, and vitamin E levels were all within normal limits. Antibody testing for paraneoplastic syndrome was negative. Previously performed normal investigations included tandem mass spectrometry for aminoacidopathies, urine for propionic aciduria, genetic testing for *DYT1* mutation, and genetic testing for Huntington's disease (CAG repeats- 25). Magnetic resonance imaging brain was normal. Fludeoxyglucose positron emission tomography (PET) brain revealed mild hypermetabolism in the bilateral caudate nuclei (Figure 1). Echocardiography revealed mild thickening of the mitral and aortic leaflets. In view of longstanding generalized chorea with the suggestion of mitral valve thickening on echocardiography and striatal hypermetabolism on the PET scan, the patient was diagnosed as a case of Sydenham's chorea. Whole-exome sequencing did not reveal any pathogenic variation. Finally, antineuronal antibodies (Cunningham panel) were markedly elevated: dopamine D1, 16,000 (normal range 500–2000); lysoganglioside, 320 (normal range 80–320); tubulin, 4,000 (normal range 250–1,000), CaM kinase II, 120 (normal range 53–130). In view of these findings, the patient was started on methylprednisolone therapy and intravenous immunoglobulin. However, the patient showed only a marginal improvement in the severity of chorea. The hyperkinetic movements decreased in amplitude. His gait improved, and violent flinging movements of the arms also decreased in intensity. Presently, the patient is on periodic cycles of methylprednisolone and intravenous immunoglobulin



**Figure 1. FDG PET Scan.** FDG PET scan showing mild hypermetabolism in bilateral caudate nuclei.



**Video 1. Video of Chorea.** Video demonstrates presence of generalized chorea with significant impairment of gait.

therapy. He is now able to feed and dress by himself, which he was unable to do previously.

### Discussion

Sydenham's chorea is a late manifestation of rheumatic fever and comprises chorea, tics, behavioral abnormalities, dysarthria, motor

impersistence, and gait disturbances.<sup>1</sup> It is usually a self-limited condition that improves in 2–6 months. Persistent Sydenham's chorea is described in 50% of cases lasting more than 2 years and is more common in women who have severe disease, with the presence of severe carditis, and with generalized chorea.<sup>2</sup> Our patient is unique because his chorea has persisted for more than 15 years from its onset and there was only mild asymptomatic cardiac involvement. The proposed pathophysiology of Sydenham's chorea involves the mechanism of molecular mimicry. Current literature highlights the role of basal ganglia autoantibodies/antineuronal antibodies in Sydenham's chorea.<sup>3</sup> These antineuronal antibodies comprise dopamine 1 receptor (D1), dopamine 2 receptor (D2), lysoganglioside GM1, and beta-tubulin. Ben-Pazi et al.<sup>4</sup> have demonstrated significantly higher anti-D1R and anti-D2R autoantibodies in patients with Sydenham's chorea than controls and their correlation with neuropsychiatric symptoms and they postulated that these autoantibodies lead to receptor imbalance and induce greater sensitivity to dopamine signaling. These antibodies are, however, not specific for Sydenham's chorea and can also occur in other conditions such as PANDAS, Tourette's syndrome, adult-onset tic disorders, obsessive compulsive disorders, and others.<sup>5,6</sup> The presence of these antibodies in our patient supports the diagnosis of Sydenham's chorea.

PET findings in Sydenham's chorea reveal hypermetabolism in the basal ganglia.<sup>7</sup> They are usually present in the acute phase and disappear with remission. Our patient also showed increase striatal glucose consumption, which may suggest ongoing inflammation and active disease. This is also emphasized by the presence of high titers of basal ganglia autoantibodies.

Treatment with intravenous immunoglobulin or plasma exchange has been found to be superior to corticosteroids in decreasing mean chorea severity scores. Our patient showed only a marginal decrease in the severity of chorea after intravenous immunoglobulin therapy.

To conclude, we present an unusual presentation of Sydenham's chorea lasting more than 15 years and highlight the utility of antineuronal antibodies in such a scenario.

### References

1. Cardoso F, Santos CEAP, Mota CC. Chorea in fifty consecutive patients with rheumatic fever. *Mov Disord* 1997;12:701–703. doi: 10.1002/mds.870120512
2. Cardoso F, Vargas AP, Oliveira LD, Guerra AA. Persistent Sydenham's chorea. *Mov Disord* 1999;14:805–807. doi: 10.1002/1531-8257(199909)14:5<805::AID-MDS1013>3.0.CO;2-P
3. Church AJ, Cardoso F, Dale RC, Lees AJ. Anti-basal ganglia antibodies in acute and persistent Sydenham's chorea. *Neurology* 2002;23:59:227–231. doi: 10.1212/WNL.59.2.227
4. Ben-Pazi H, Stoner JA, Cunningham MW. Dopamine receptor autoantibodies correlate with symptoms in Sydenham's chorea. *PLoS One* 2013;20:8:e 73516. doi: 10.1371/journal.pone.0073516

5. Church AJ, Dale RC, Giovannoni G. Anti-basal ganglia antibodies: a possible diagnostic utility in idiopathic movement disorders? *Arch Dis Child* 2004;89:611–614. doi: 10.1136/adc.2003.031880
6. Edwards MJ, Dale RC, Church AJ et al. Adult onset tic disorder, motor stereotypies, and behavioral disturbance associated with antibasal ganglia antibodies. *Mov Disord* 2004;19:1190–1196. doi: 10.1002/mds.20126
7. Aron AM. Sydenham's chorea: positron emission tomographic (PET) scan studies. *J Child Neurol* 2005;20:832–833. doi: 10.1177/08830738050200101101